

# After Arterial Switch Surgery Myocardial Performance Index Left Ventricular Function does it Provide as much Information as a Cardiac MRI?

© Kaan Yıldız<sup>1</sup>, © Yasin Ertuğ Çekdemir<sup>2</sup>, © Muhammet Salman<sup>2</sup>, © Mustafa Kır<sup>1</sup>,  
© Handan Güteryüz<sup>2</sup>, © Öztekin Oto<sup>3</sup>, © Nurettin Ünal<sup>1</sup>

<sup>1</sup>Dokuz Eylül University Faculty of Medicine, Department of Pediatric Cardiology, İzmir, Turkey

<sup>2</sup>Dokuz Eylül University Faculty of Medicine, Department of Radiology, İzmir, Turkey

<sup>3</sup>Dokuz Eylül University Faculty of Medicine, Department of Cardiovascular Surgery, İzmir, Turkey

## Abstract

**Objectives:** In this study, a comparison of cardiac magnetic resonance imaging (MRI) and simultaneous transthoracic echocardiography data were obtained from patients with great artery transposition (TGA), who underwent arterial switch operation (ASO) surgery. In to discover the most effective and optimal viewing method during long-term follow-ups.

**Materials and Methods:** This retrospective cohort included 20 TGA patients (16 male, 4 female), which had ASO surgery. Along with cardiac MRI and transthoracic echocardiography data were obtained from the images. The mean age was 93.00±29.82 months (60-144). Seventeen patients had TGA only. However, 3 patients with TGA included an existing ventricular septal defect.

**Results:** We showed a meaningful correlation between echocardiographic variables (left ventricle dilatation of the left ventricle function of the aorta failure, myocardial performance index) and MRI parameters (ejection fraction of left ventricle dilatation of the left ventricle function of the aorta insufficiency).



**Address for Correspondence:** Kaan Yıldız, Dokuz Eylül University Faculty of Medicine, Department of Pediatric Cardiology, İzmir, Turkey

**Phone:** +90 532 215 37 35 **e-mail:** drkaanyildiz@gmail.com **ORCID:** orcid.org/0000-0001-9722-6994

**Received:** 27.12.2022 **Accepted:** 27.02.2023

**Cite this article as:** Yıldız K, Çekdemir YE, Salman M, Kır M, Güteryüz H, Oto Ö, Ünal N. After Arterial Switch Surgery Myocardial Performance Index Left Ventricular Function does it Provide as much Information as a Cardiac MRI?. EJCM2023;11(1):23-30.

DOI: 10.32596/ejcm.galenos.2023.2022-12-057

**Conclusion:** TGA patients require careful pre and post operative evaluation, anatomical and a functional use of cardiac indicators. For this purpose, both echocardiography and MRI are useful, safe, and trustworthy methods of diagnosis. Choosing the optimal imaging technique and lifetime reoccurring assessments of the left ventricle function is of vital importance in foreseeing complications, preventing morbidities, and creating a protocol. In clinical practice, the myocardium performance index provides values similar to that of the MRI about the left ventricle dilatation and left ventricle dysfunction. These results provide awareness about the use of specific parameters and the use of information based on quantitative data.

**Keywords:** Great artery transposition, arterial switch, myocardial performance index, echocardiography, magnetic resonance imaging, pediatric

## Introduction

In the long-term follow-up of patients undergoing arterial switch operation (ASO), the left ventricle (LV) functions, which is the systemic ventricle, are of primary importance. Various non-invasive diagnostic methods are available for the diagnosis of pediatric congenital heart diseases and for the determination of ventricular functions<sup>(1)</sup>. Two dimensional echocardiography is the most widely used method in clinical practice. Although echocardiography is a common, inexpensive and non-invasive method, it depends on the operator and in some cases, the desired quality images may not be obtained due to the limited acoustic windows<sup>(2)</sup>.

Cardiac magnetic resonance imaging (MRI) is another non-invasive technique used to determine LV function. Cardiac MRI, with its high spatial resolution and three-dimensional representation of structures, is an excellent technique for evaluating both left and right ventricular function. Highly accurate and reproducible quantitative measurements can be obtained with multiplane imaging in compliant patients without sedation<sup>(3,4)</sup>. Cardiac MRI cannot be performed in all centers because it requires a special technique and interpretation by experienced specialists. Data obtained with the correct imaging technique in cardiac MRI minimize operator-related errors that may occur in echocardiography<sup>(5)</sup>. Serial imaging should be performed in patients undergoing ASO to demonstrate structural changes in tissues associated with

surgery. Cardiac MRI has been used frequently recently to evaluate ventricular functions, to measure the peak rates of regurgitation in the aorta and pulmonary arteries, and to show stenosis<sup>(6)</sup>. On the other hand, different parameters obtained from echocardiographic variables can be used to evaluate LV functions similar to that of an MRI and provide beneficial and sufficient data. A method is a tissue Doppler echocardiography myocardium, which can give information about diastolic performance directly, independent of the cardiac preload. The interpretation of speed values obtained by measurement of diastolic time intervals and different examination positions can be used to evaluate diastolic functions at a local and global level. The early detection of the loss of diastolic function before that of the systolic function is possible with a tissue Doppler and myocardium performance index (MPI)<sup>(7,8)</sup>.

Our aim was to compare transthoracic echocardiography (TTE) and tissue Doppler findings and discover the most optimal and effective imaging method in TGA patients undergoing ASO for long-term follow-up.

## Materials and Methods

This retrospective cohort was conducted between 01.09.2018 and 31.08.2019 in the radiology and pediatric cardiology departments of the tertiary health center. It has been ensured that the principles of confidentiality of the identity and medical information of the patients are strictly adhered to.

Cardiac MRI and TTE images obtained from the hospital records of 20 TGA patients (16 boys, 4 girls) were analyzed retrospectively. The mean age was  $93.00 \pm 29.82$  months (range: 60-144). Seventeen patients had TGA only, and 3 patients had TGA together with VSD.

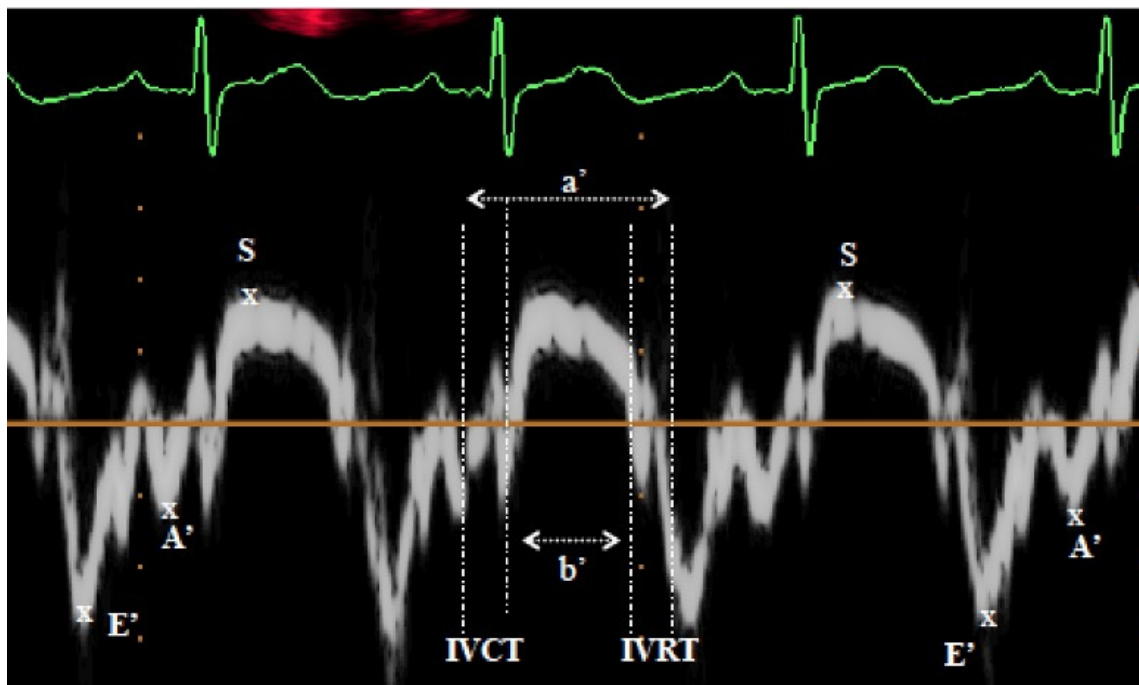
It was planned to reach all patients with available cardiac MRI and concurrent echocardiography recording; therefore, so the exact number of patients was unpredictable. It is planned to compare and evaluate the parametric findings detected in cardiac MRI and echocardiography. The compatibility of techniques and their advantages over each other in determining LV functions and valve regurgitation in patients undergoing ASO for TGA was investigated using numerical measurements. Inclusion criteria were TGA patients aged 5 years and older who had undergone ASO and had no history of sedation or anesthesia. The study was approved by the Ethics Committee of Dokuz Eylül University Faculty of Medicine (approval no: 2018/20-38, date: 02.08.2018).

## TTE

The TTE examination using the Philips Affinite 50c system (Philips, Netherlands) was carried out. Consecutive cardiac loops with enough technical quality were repeated thrice to provide a measurement for analysis. LV functions four apical chamber and parasternal long axis in their windows were evaluated. Aorta lid insufficiency was viewed using an apical five-chamber window. The tissue Doppler method with MPI was measured. Echocardiographic measurements for MPI were obtained from the apical four-chamber view. A cursor was placed on the myocardial segment of the left ventricular posterior wall and interventricular septum. Myocardial tissue velocities were recorded by placing pulsed wave tissue Doppler at the level of the basal segments of each.

## MRI

MRI 1.5 Tesla Philips Ingenia system (Philips, Netherlands) performed. All patients had a regular cardiac rhythm, and ventricular visualization was achieved using cine images starting from the entry point of the ventricles,



**Figure 1.** Identification of signals obtained by tissue Doppler echocardiography

leading to the apex at a orthogonal long axis of the LV with more than 10 mm adjacent breath holding.

Ventricular mass was calculated using end-diastole epicardial and endocardial surfaces. Myocardial volume applied the Simpson's rule for calculation, and myocardial mass density was accepted as 1.05 g/m<sup>3</sup>. Septum was accepted as part of the LV, and end-systole endocardial-volume measurements were used for the calculation of the ejection fraction.

### Outcome Measures

LV and aorta lid functions were digitally calculated as parameters. Echocardiograms with tissue Doppler get MPI, neoaorta and neopulmonary artery diameters and deficiencies, visibility of right and left pulmonary artery branches, LV dilatation, ejection fraction, systolic, and diastolic functions were considered. Cardiac LV function in MRI values, aorta, and pulmonary artery functions with dynamic MR views were calculated by digital aspects. LV ejection with cardiac MRI fraction, LV end diastolic and systolic volumes of neoaortic with neopulmonary artery diameters and deficiencies, and right and left pulmonary artery visibility are evaluated. In this study, LV function values, aorta, and pulmonary lid function using MR and echocardiography were the parameters determined as dependent variables.

### Echocardiography Variables

1. With or without LV dilatation specified. If the LV volume was larger than the right ventricle (RV) volume, it was accepted as a pathological result.

2. LV dysfunction were defined as, without: 1, with: 2

3. Measurements for aorta lid insufficiency were calculated according to the apical five -chamber window and its length of jet. 1: normal, 2: mild, 3: moderate, 4: significant

4. The calculation was performed in accordance with the study of MPI, MPI = (isovolemic contraction duration + isovolemic relaxation duration)/ejection duration<sup>(9)</sup>.

### Statistical Analysis

Descriptive statistics for digital variables average, standard deviation, minimum, and maximum values with categorical variables for number and percent values are given. The correlation values between indicators and other data types with different correlation (pearson, tetracolic, polychoric and eta correlation coefficients) coefficients are examined. Analysis was carried out using the IBM SPSS program version 21.0.

### Results

In our study, basic patient information is presented in Table 1. Our patient population (n=20) consisted of 16 men with a mean age of 93.00±29.82 months (range: 60-144) and 4 women. In 17 patients, only TGA was seen; with TGA in 3 patients together, there was VSD. The mean body mass index is 16.37±2.34 kg/m<sup>2</sup> and mean age for ASO was 7.30±10.53 days.

The data obtained from this series of echocardiography and MRI are shown in Table 2. During the echocardiography

**Table 1.** Baseline descriptives for demographic data

		Number	Percentage
Gender	Female	4	20.0
	Male	16	80.0
Diagnosis	TGA	17	85.0
	TGA + VSD	3	15.0
		<b>Mean - Standard deviation</b>	<b>Min.-Max.</b>
Age (months)		93-29.82	60-144
Age at the time of ASO (days)		7.30-10.53	1-48
BMI (kg/m <sup>2</sup> )		16.37-2.34	12.9-23.2

TGA: Transposition of the great arteries, VSD: Ventricular septal defect, ASO: Arterial switch operation, BMI: body-mass index, Min.: minimum, Max.: maximum

of one patient, LV dilatation and dysfunction detection was observed. The MPI average was  $0.38 \pm 0.04$ .

In one patient, LV dilation and dysfunction was detected from MRI images. The average values of LV end diastolic volume and ejection fraction for values were  $78.98 \pm 47.21$  and  $62.43 \pm 7.52$ , respectively. The average degree of aorta failure (%) was 8.138.

Table 3, summarizes the echocardiographic and MRI variables between the relationship correlation matrix. Analysis of our data of LV dilatation on echocardiography,

LV end systolic volume on MRI ( $r=0.75$ ), LV dysfunction ( $r=0.99$ ), and aorta failure degree ( $r=0.90$ ) revealed a strong and positive relationship.

In echocardiography aortic failure LV dilatation ( $r=0.92$ ) and LV dysfunction ( $r=0.94$ ) on MRI showed a strong and positive correlation. In echocardiography, aortic failure with the LV ejection fraction displayed an opposite relationship ( $r=-0.85$ ).

MPI, LV dilatation ( $r=0.81$ ), and LV dysfunction ( $r=0.94$ ) on MRI had a strong and positive correlation.

**Table 2.** Descriptive data for echocardiography and magnetic resonance imaging parameters for our series

		Mean (Number)	Standard deviation (%)	Minimum	Maximum
<b>Echocardiography</b>					
LV dilatation	No	19	95.0		
	Yes	1	5.0		
LV function	No	1	5.0		
	Yes	19	95.0		
AI grade	1	13	65.0		
	2	5	25.0		
	3	1	5.0		
	4	1	5.0		
MPI		0.38	0.04	0.30	0.43
<b>MRI</b>					
LVEDV		78.98	47.21	44	270
LVEF		62.43	7.52	50	75
LV dilatation	No	19	95.0		
	Yes	1	5.0		
LV function	No	3	5.0		
	Yes	17	95.0		
AI %		8.13	13.48	0.80	43.5

LV: Left ventricular, AI: Aortic insufficiency, MPI: Myocardial performance index, EF: Ejection fraction, LVEDV: Left ventricular end diastolic volume, MR: Magnetic resonance

**Table 3.** Correlation matrix for the relationship between parameters derived from echocardiography and magnetic resonance imaging

		Magnetic resonance imaging					
		LVEDV	LV (EF)	LV dilatation	LV function	Root of aorta	AI %
Echocardiography	LV dilatation	0.75	<b>0.40</b>	<b>1.00</b>	<b>0.99</b>	0.36	<b>0.90</b>
	LV function	0.93	<b>-0.88</b>	<b>0.98</b>	<b>1.00</b>	0.38	<b>0.94</b>
	AI	0.05	<b>-0.85</b>	<b>0.92</b>	<b>0.94</b>	0.82	<b>0.95</b>
	LV (MPI)	0.31	0.12	<b>0.81</b>	<b>0.93</b>	<b>-0.19</b>	0.91
	Root of Aorta	0.23	0.28	<b>0.23</b>	<b>0.93</b>	0.65	<b>0.89</b>

Bold figures indicate high degree of relationship, while negative figures indicate an inverse relationship between variables

LV: Left ventricular, AI: Aortic insufficiency, MPI: Myocardial performance index, EF: Ejection fraction, LVEDV: Right ventricular end diastolic volume

Echocardiography of LV with MPI in MRI between aortic roots had an opposite relationship ( $r=-0.19$ ).

## Discussion

LV dysfunction can be seen in patients who underwent an ASO. Careful monitoring and follow-up are essential for the prediction and prevention of complications that may lead to morbidity and mortality<sup>(10)</sup>. In this patient group, evaluation of the hemodynamic profile for multiple viewing methods was confirmed. There have been significant advances in the clinical diagnosis and treatment of patients with TGA due to the utility of recent advancements in viewing methods. TGA patients require lengthy surveyance due to their recurring anatomic and hemodynamic abnormalities. Therefore, TGA patients undergoing ASO require an optimal viewing protocol and an integrated algorithm. The widespread availability and utility of an echocardiography is the factor for its essential role in the diagnosis of TGA in patients. Two-dimensional TTE and Doppler echocardiography provide sufficient information about the anatomical and hemodynamic evaluation before operations. TTE can be used during the postoperative period for recognition of residual, recurrent, or new pathologies<sup>(11,12)</sup>.

On the other hand, in TGA patients, especially after an operation, an MRI of both cardiac anatomy and function can provide valuable information. Cardiovascular MRI is the gold standard in analyzing the size of LV and function quantitatively. MRI provides high-quality images without any ionizer radiation. An MRI can be performed to evaluate myocardial performance and vitality along with a reliable assessment of lid functions and extracardiac structures. For MRI, the most important disadvantage is that it requires the patient to be still for about 30 to 45 min. In these cases, sedation or anesthesia may be required<sup>(4,13)</sup>.

There can be difficulties in observing the pulmonary branches during echocardiographic imaging in cases where the LeCompte maneuver is performed in TGA patients undergoing secondary ASO, due to the disruption of the acoustic window<sup>(14)</sup>. In our study in TTE, low detection

levels of right and left pulmonary artery branches have been observed. Pulmonary arteries were clearly visible during the cardiac MRI and the necessary measurements could be performed. In our study, the branches of the pulmonary artery could not be visualized adequately in TTE, and the stenosis in the pulmonary artery could not be evaluated. In cardiac MRI, stenosis in the pulmonary artery bifurcation area is clearly shown.

Aortic root measurements and aortic insufficiency degree revealed similar results to that of previous literature publications<sup>(15,16)</sup>. Our results are three-dimensional to your character attributed atrial dimension and your function to the evaluation and myocardial your border perfect one way to the definition permission given for ASO applied patients for advanced one-choice method aspect cardiac of MRI the benefit other in studies is support<sup>(17)</sup>. Our results highlight the benefit of an MRI as an improved method of imaging for patients who underwent TGA, as was seen in other studies. Allowing for perfect evaluation of the myocardial border and a three-dimensional character attributed to the atrial dimension and function<sup>(16)</sup>.

MPI, is a non-geometric index for ventricular function. It is easily applicable to evaluate the function of the Right and LV. Also, MPI's are not affected by blood pressure, heart speed, and ventricle geometry. Therefore, MPI has a great prognostic value in different clinical situations. In the study, a correlation was shown between ventricle function and MPI measurements of an MRI performed in the following 90 days to evaluate RV functions compared with an MPI<sup>(17)</sup>. A report regarding pediatric patients with a heart transplant provided 85% specificity and 82.5% sensitivity for acute cardiac rejection<sup>(18,19)</sup>. With dilated cardiomyopathy in patients made one in the study, a study concerning dilated cardiomyopathy patients highlighted the advantage of using the MPI ejection fraction and the LV independently on predicting patients with a risk of cardiovascular mortality from heart failure<sup>(20)</sup>. In our study with tissue Doppler data, a strong and positive correlation was shown for MPI, LV dilatation on MRI, and LV dysfunction. This compatibility provides an alternative

important contribution for evaluating LV function in young patients who require sedation for an MRI or are clinically unsuitable for MRI. Patients with good systolic function but high MPI may develop ventricular dysfunction before clinical indication; therefore, it is vital and practical in prognosis and follow-up.

### Study Limitations

The weakest aspect of this study is that it is a retrospective study with data from a single center with a small sample size. Additionally, parameters derived from MRI and echocardiography require further verification compared with other invasive and non-invasive methods. Also, long-term confirmation of our results can provide more correct data.

### Conclusion

TGA patients require careful pre and post operative evaluation, anatomical and a functional use of cardiac indicators. For this purpose, both echocardiography and MRI are useful, safe, and trustworthy methods of diagnosis. Choosing the optimal imaging technique and lifetime reoccurring assessments of the LV function is of vital importance in foreseeing complications, preventing morbidities, and creating a protocol. In clinical practice, MPI, can provide values close to an MRI about LV dilatation and LV dysfunction. These results raise awareness about the importance of specific parameters in using information based on quantitative data. These results raise awareness about the importance of specific parameters in using information based on quantitative data.

### Ethics

**Ethics Committee Approval:** The study was approved by the Ethics Committee of Dokuz Eylül University Faculty of Medicine (approval no: 2018/20-38, date: 02.08.2018).

**Informed Consent:** Informed consent was obtained from all patients.

**Peer-review:** Externally peer-reviewed.

### Authorship Contributions

Surgical and Medical Practices: Güteryüz H, Oto Ö, Ünal N, Concept: Yıldız K, Ünal N, Design: Yıldız K, Çekdemir YE, Data Collection and/or Processing: Çekdemir YE, Salman M, Analysis and/or Interpretation: Salman M, Literature Search: Yıldız K, Writing: Yıldız K.

**Conflict of Interest:** No conflict of interest was declared by the authors.

**Financial Disclosure:** This research received no specific grant from any funding agency.

### References

1. Pettersen E, Fredriksen PM, Urheim S, et al. Ventricular function in patients with transposition of the great arteries operated with arterial switch. *Am J Cardiol* 2009;104:583-9.
2. Prakash A, Powell AJ, Geva T. Multimodality noninvasive imaging for assessment of congenital heart disease. *Circ Cardiovasc Imaging* 2010;3:112-25.
3. Dorfman AL, Geva T. Magnetic resonance imaging evaluation of congenital heart disease: conotruncal anomalies. *J Cardiovasc Magn Reson* 2006;8:645-59.
4. Odegard KC, DiNardo JA, Tsai-Goodman B, Powell AJ, Geva T, Laussen PC. Anaesthesia considerations for cardiac MRI in infants and small children. *Paediatr Anaesth* 2004;14:471-6.
5. Burman ED, Keegan J, Kilner PJ. Aortic root measurement by cardiovascular magnetic resonance: specification of planes and lines of measurement and corresponding normal values. *Circ Cardiovasc Imaging* 2008;1:104-13.
6. Tobler D, Motwani M, Wald RM, et al. Evaluation of a comprehensive cardiovascular magnetic resonance protocol in young adults late after the arterial switch operation for d-transposition of the great arteries. *J Cardiovasc Magn Reson* 2014;16:98.
7. Öner T, Özdemir R, Güven B, et al. Evaluation of myocardial function in pediatric patients with transposition of great arteries after arterial switch operation. *Anatol J Cardiol* 2016;16:55-61.
8. Sobeih AA, El-Baz MS, El-Shemy DM, Abu El-Hamed WA. Tissue Doppler imaging versus conventional echocardiography in assessment of cardiac diastolic function in full term neonates with perinatal asphyxia. *J Matern Fetal Neonatal Med* 2021;34:3896-901.
9. Tham EB, Silverman NH. Measurement of the Tei index: a comparison of M-mode and pulse Doppler methods. *J Am Soc Echocardiogr* 2004;17:1259-65.
10. Ruys TP, van der Bosch AE, Cuypers JA, et al. Long-term outcome and quality of life after arterial switch operation: a prospective study with a historical comparison. *Congenit Heart Dis* 2013;8:203-10.
11. de Roos A. Role of Cardiovascular Magnetic Resonance Imaging in Postoperative Follow-Up After the Arterial Switch Operation

- for Transposition of the Great Arteries. *Circ Cardiovasc Imaging* 2016;9:e005463.
12. Cohen MS, Eidem BW, Cetta F, et al. Multimodality Imaging Guidelines of Patients with Transposition of the Great Arteries: A Report from the American Society of Echocardiography Developed in Collaboration with the Society for Cardiovascular Magnetic Resonance and the Society of Cardiovascular Computed Tomography. *J Am Soc Echocardiogr* 2016;29:571-621.
  13. Gabbour M, Schnell S, Jarvis K, Robinson JD, Markl M, Rigsby CK. 4-D flow magnetic resonance imaging: blood flow quantification compared to 2-D phase-contrast magnetic resonance imaging and Doppler echocardiography. *Pediatr Radiol* 2015;45:804-13.
  14. Rickers C, Kheradvar A, Sievers HH, et al. Is the Lecompte technique the last word on transposition of the great arteries repair for all patients? A magnetic resonance imaging study including a spiral technique two decades postoperatively. *Interact Cardiovasc Thorac Surg* 2016;22:817-25.
  15. Shepard CW, Germanakis I, White MT, Powell AJ, Co-Vu J, Geva T. Cardiovascular Magnetic Resonance Findings Late After the Arterial Switch Operation. *Circ Cardiovasc Imaging* 2016;9:e004618.
  16. Schwartz ML, Gauvreau K, del Nido P, Mayer JE, Colan SD. Long-term predictors of aortic root dilation and aortic regurgitation after arterial switch operation. *Circulation* 2004;110:II128-32.
  17. van Wijk WHS, Breur JMPJ, Westenberg JJM, et al. Validation of aortic valve 4D flow analysis and myocardial deformation by cardiovascular magnetic resonance in patients after the arterial switch operation. *J Cardiovasc Magn Reson* 2019;21:20.
  18. Salehian O, Schwerzmann M, Merchant N, Webb GD, Siu SC, Therrien J. Assessment of systemic right ventricular function in patients with transposition of the great arteries using the myocardial performance index: comparison with cardiac magnetic resonance imaging. *Circulation* 2004;110:3229-33.
  19. Lunze FI, Singh TP, Gauvreau K, et al. Comparison of tissue Doppler imaging and conventional echocardiography to discriminate rejection from non-rejection after pediatric heart transplantation. *Pediatr Transplant* 2020;24:e13738.
  20. Tei C, Ling LH, Hodge DO, et al. New index of combined systolic and diastolic myocardial performance: a simple and reproducible measure of cardiac function--a study in normals and dilated cardiomyopathy. *J Cardiol* 1995;26:357-66.